

# Middle ear cholesteatoma in two cats diagnosed with the aid of video-otoscopy

Cristiane Bazaga Botelho<sup>1</sup>, Rafaella Tortoriello<sup>1</sup> ,  
Sandra Nogueira Koch<sup>2</sup>, Natália Lôres Lopes<sup>1</sup> ,  
Ronaldo Lucas<sup>3</sup> and Julio Israel Fernandes<sup>1</sup>

*Journal of Feline Medicine and Surgery Open Reports*  
1–5

© The Author(s) 2023

Article reuse guidelines:

sagepub.com/journals-permissions

DOI: 10.1177/20551169231196528

journals.sagepub.com/home/jfmsopenreports

This paper was handled and processed by the American Editorial Office (AAFP) for publication in *JFMS Open Reports*



## Abstract

**Case series summary** The present report describes middle ear cholesteatoma in two cats and also the use of video-otoscopy and flushing to assist with the diagnosis. CT and video-otoscopic examination and flushing were performed in two cats, a 13-year-old mixed breed spayed female cat and a 1-year-old mixed breed male cat, with middle ear cholesteatomas. During the procedure, keratinous material from the middle ears was collected for histopathological evaluation, demonstrating findings consistent with cholesteatoma, and the middle ears were flushed extensively.

**Relevance and novel information** There is little information about middle ear cholesteatoma in cats, and to the authors' knowledge, there are no reports in cats investigating the use of video-otoscopy to aid in the diagnosis of aural cholesteatoma, and this report demonstrates that it can aid in the diagnosis of this condition in cats. In addition, one of the cats had a concurrent otic polyp, which has not been previously reported in cats with cholesteatoma. Additionally, this is the first report of cholesteatoma in a young cat. The access to the cholesteatoma material was via ventral bulla osteotomy in one cat and via external canal without video-otoscopy in the other. More information regarding cholesteatoma in cats will help identify potential similarities and differences of this condition in cats compared with humans and dogs.

**Keywords:** Cholesteatoma; ear; video-otoscopy; histopathology

**Accepted:** 4 August 2023

## Introduction

Cholesteatoma, also known as tympanokeratoma, is a cystic structure filled with keratinized squamous epithelium within the middle ear that can expand and be locally invasive and aggressive, especially with advanced disease.<sup>1–6</sup> Material can protrude into the external canal.<sup>1–6</sup> There is limited information of aural cholesteatoma in cats, with only two cases reported in the literature.<sup>7,8</sup>

Aural cholesteatoma has been uncommonly reported in dogs.<sup>1–5</sup> The diagnosis of cholesteatoma in dogs is usually performed by CT, video-otoscopy with visualization of characteristic pearly white or yellow growth through the external ear canal, and histopathology.<sup>2,5</sup> The recommended treatment in dogs is surgical removal,

which can be curative in less severe cases, but recurrence is common with chronic disease.<sup>2</sup>

<sup>1</sup>Veterinary Institute, Federal Rural University of Rio de Janeiro, Seropédica, Brazil

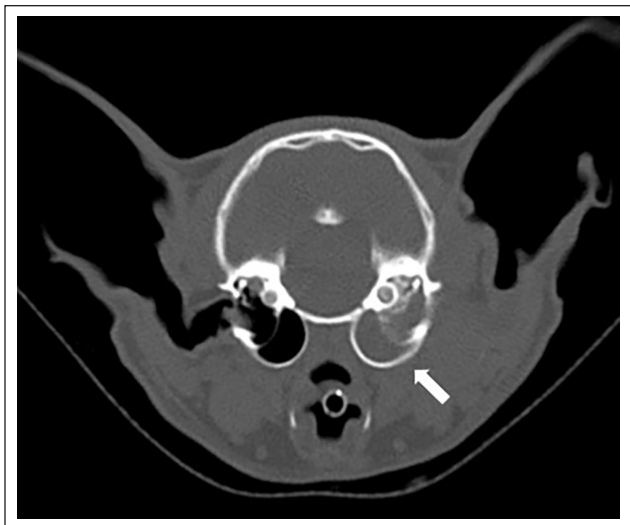
<sup>2</sup>Veterinary Clinical Sciences Department, College of Veterinary Medicine, University of Minnesota, Saint Paul, MN, USA

<sup>3</sup>Veterinary, DSc Dermatoclínica, São Paulo, SP, Brazil

### Corresponding author:

Cristiane Bazaga Botelho, PhD, Veterinary Institute, Federal Rural University of Rio de Janeiro, Rua David Pérez 126–Barra da Tijuca/Rio de Janeiro, Seropédica, 23897-000, Brazil  
Email: vetcris@gmail.com





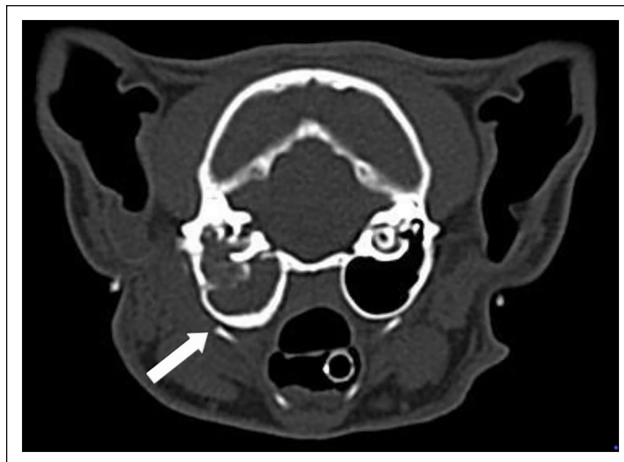**Figure 1** CT findings of aural cholesteatoma (case 1). CT revealed complete filling of the left external ear canal with hypodense material. Complete obliteration of the left tympanic bulla by soft tissue hypodense material and more attenuating material was revealed, with discrete foci of mineralization in the lateral ventral portion and density in the ventromedial portion of the bulla. The presence of central osteophytes, 1 mm in diameter, was also found. White arrow indicates the affected bulla

To the authors' knowledge, this is the first report of middle ear cholesteatoma in cats diagnosed with video-otoscopy.

### Case series description

One 13-year-old mixed breed spayed female cat (case 1) and one 1-year-old mixed breed castrated male cat (case 2) presented to a private clinic with a history of chronic unilateral otitis externa (case 1 in the left ear; case 2 in the right ear) with otic pruritus and discomfort that had been unresponsive to previous medical therapies. Case 1 also had acute nystagmus, head tilt and ataxia. The age of onset of the clinical signs were 11 years (case 1) and 6 months (case 2), respectively. Otoscopic examination revealed unilateral discharge obscuring the tympanic membranes, and so could not be visualized. CT and video-otoscopy examinations were performed in both cats under general anesthesia and, after the procedures, no pain medication was prescribed.

CT scan (case 1 in the left ear; case 2 in the right ear) showed involvement of the external ear canals and middle ears (Figures 1 and 2). Video-otoscopy (MDS-Vet endoscope) and ear flushing with sterile saline were performed. In case 1, after flushing, pale/tan pearly homogeneous friable keratinous material was present deep in the horizontal external ear canal, protruding from the middle ear cavity (Figure 3). After ear flushing in case 2, a pink dome-shaped mass was noted in the horizontal

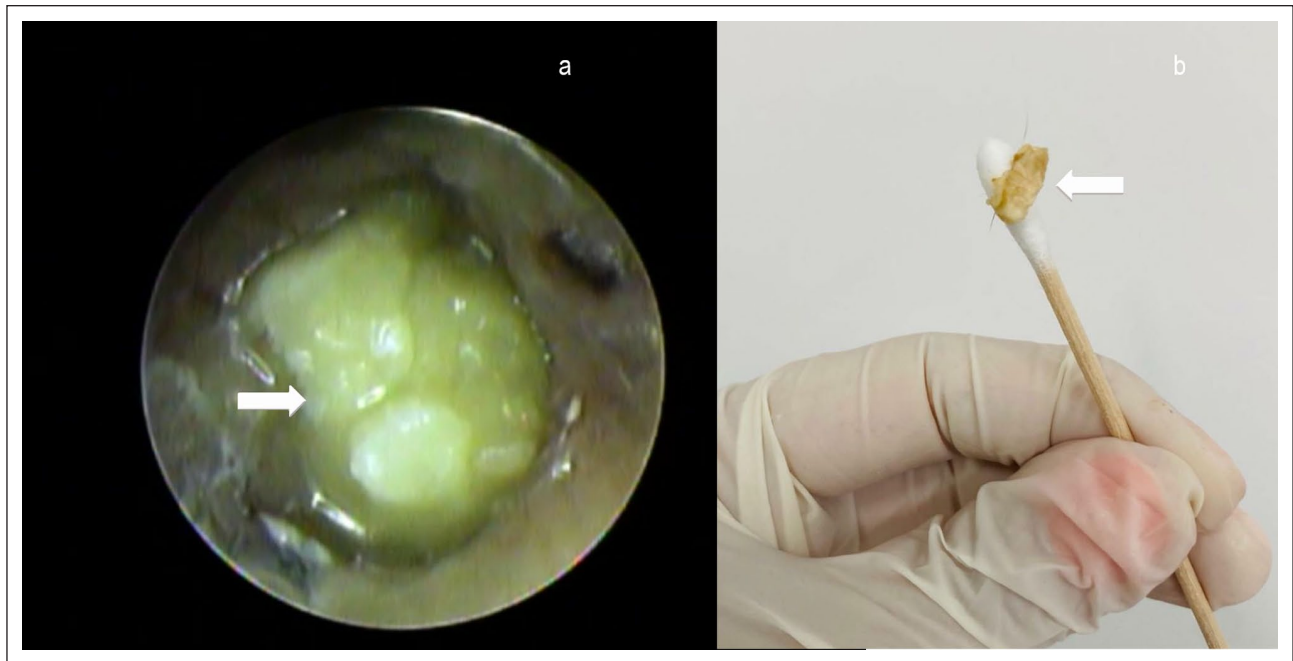


**Figure 2** CT findings of aural cholesteatoma (case 2). CT revealed complete obstruction of the right external ear canal by hypodense material and the presence of mixed contrast attenuation with some soft tissue-like material that completely filled the right tympanic cavity with mild expansion and sclerosis of the bulla. White arrow indicates the affected bulla

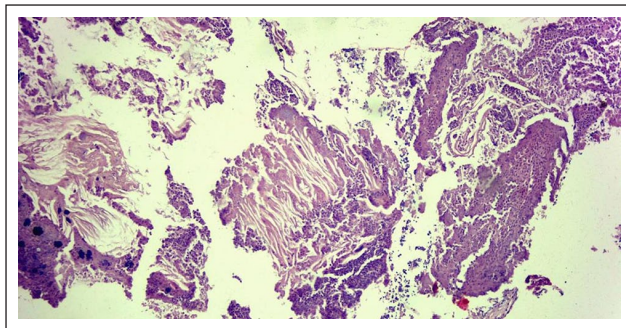
ear canal protruding from the middle ear, which was removed by traction, allowing visualization of pale/tan pearly homogeneous friable keratinous material present in the middle ear. The tympanic membranes in both cats were absent. Keratinous samples were collected from the horizontal canal and bulla using 5-fringe biopsy forceps through video-otoscopy for cytology, aerobic culture and histopathology. After sampling, the bulla was flushed as much as possible with a copious amount of sterile saline and all visible keratinous material was removed. Additionally, the suspected polyp in case 2 was submitted for histopathological evaluation.

Histopathology for both cats showed amorphous necrotic cellular debris with few foci of neutrophilic inflammation, as well as fragments of mildly dysplastic squamous epithelium and aggregates of keratin (Figure 4). These findings, along with the clinical characteristics and collection sites, were consistent with cholesteatomas. In case 2, histopathology confirmed an inflammatory polyp (Figure 5) and bacterial culture found *Pseudomonas aeruginosa*.

Treatment after flushing and removal of debris included topical compounded otic saline solution of 0.1% dexamethasone and 0.35% ciprofloxacin twice daily for 3 weeks and a tapering course of prednisolone at 1 mg/kg PO q24h for 7 days, then 0.5 mg/kg q24h for 7 days. Pain medication was not prescribed. Ventral bulla osteotomy was recommended, although the owners declined this. Maintenance treatment was not instituted. Both cats were re-evaluated after 1 month (case 1) and 6 months (case 2), respectively, using an otoscope (MacroView; Welch

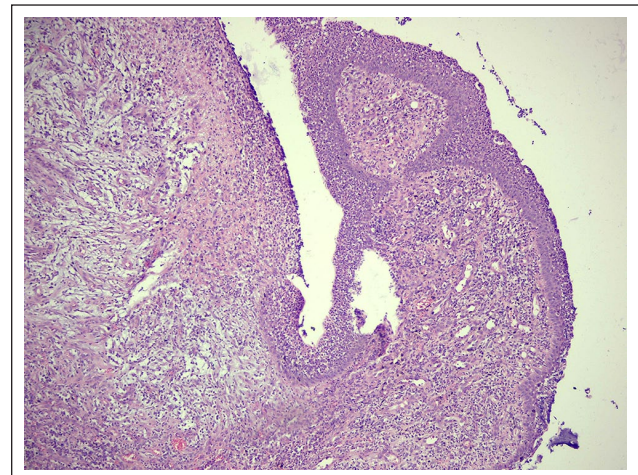


**Figure 3** Video-otoscopy of cholesteatoma in a cat (case 1): (a) visualization of pale/tan pearly homogeneous friable material (white arrow) with a smooth surface in the left middle ear; and (b) cholesteatoma fragments (white arrow) present on a swab collected from the left ear



**Figure 4** Histological sections of the aural cholesteatoma in a cat (case 1), showing the presence of amorphous material containing cellular and necrotic debris and focal neutrophilic inflammation, associated with fragmented anucleated cornified lamellae sheets

Allyn). In case 1, the ear canal was without exudate, but the tympanic membrane was not intact. On case 2, the ear canal was clear and without exudate and the tympanic membrane had healed. Both cases had no reported recurrence at that time based on historical, clinical and otoscopic evaluations. Video-otoscopy and CT scan under general anesthesia were not repeated due to the owners' financial limitations. Unfortunately, the follow-up time for both cats was shorter than ideal. Cat 1 was euthanized due to chronic kidney disease, and cat 2 did not follow-up for examination but was reportedly doing well on consultation over the telephone.



**Figure 5** Histological sections (case 2) showing a polypoid nodule, consisting of fibrovascular tissue containing low-to-moderate cellularity and moderate vascularity, marked mixed inflammatory infiltrate characterized by lymphocytes and plasmacytes, and macrophages rich in neutrophils under the ulcerated region. Partially ulcerated non-keratinized nodule with columnar ciliated epithelium and the presence of lymphoid follicles is also shown

## Discussion

Cholesteatoma is a middle ear disease of poorly understood etiopathogenesis described in humans and uncommonly in dogs.<sup>2-6,9,10</sup> This report describes two cases of feline aural cholesteatoma. To the authors' knowledge,

there are two reports of cholesteatoma in cats,<sup>7,8</sup> where the diagnosis was through the oral cavity and external canal via needle-and-grab biopsies, blindly without video-otoscopy, in one cat and through ventral bulla osteotomy in the other cat. By contrast, for the cats in this report, video-otoscopy was used, allowing visualization of the characteristic cholesteatoma and sampling through the external canal. The blind collection of otic material for histopathological evaluation without the use of video-otoscopy may lead to sampling of non-representative material for diagnosis of cholesteatoma.

Chronic ear inflammation and infection are suspected to play a role in the development of cholesteatoma in humans and dogs, and was speculated to be the cause of the cholesteatoma reported in one cat; chronic otitis externa also occurred in the cat in this report.<sup>7</sup>

In previous reports,<sup>7,8</sup> there were 13 years and 11 months between the age of onset of clinical signs and diagnosis for each cat, respectively, while in the two cats reported here, periods of 2 years (case 1) and 6 months (case 2) were reported, respectively. Additionally, one of the cats was older at the time of diagnosis (case 1), similar to the two previously reported cases;<sup>7,8</sup> however, the other cat in this report (case 2) was only 1 year old, demonstrating the occurrence of cholesteatoma in a young cat for the first time.

The majority of cases reported in dogs have been in middle-aged animals;<sup>11</sup> owing to few cases reported in cats, it is not possible to correlate such prevalence. It is possible that this condition is misdiagnosed in cats because clinicians may not be familiar with the appearance of cholesteatoma, considering that it can be confused with otic debris. Moreover, it may be difficult to collect the entire cholesteatoma cyst through video-otoscopic access because the cystic lining can rupture and only keratinous debris may be collected.<sup>11</sup> The presence of the findings of keratinic material and connective tissue in the middle ear has been considered adequate to diagnose cholesteatoma.<sup>2,8,11,12</sup> However, an otologic history and otoscopic examination with histopathological findings and advanced imaging are important to support the diagnosis.<sup>2,3,5,7,8,11,12</sup>

Clinical signs in dogs include otorrhea, ear scratching, head shaking, pain and neurological signs.<sup>2,4,5</sup> By contrast, the clinical signs reported in the first feline report<sup>7</sup> were lethargy, vocalization and snorting with late onset of neurological signs, while in the other report,<sup>8</sup> unilateral Horner and facial nerve paralysis were present. In this report, both cats had unilateral otitis and case 1 had neurological signs, similar to dogs and the first feline report.<sup>7</sup> The youngest cat (case 2) also had an aural polyp, similar to the first feline case reported, which had an oropharyngeal polyp.<sup>7</sup>

Interestingly, in humans, aural polyps can be a predictor for cholesteatomas.<sup>9</sup> A possible association of cholesteatoma and polyps has also been speculated in dogs.<sup>5</sup> It is possible that polyps in cats play a role in the development of cholesteatoma. Young cats are predisposed to polyps, which can cause similar clinical signs to keratin cysts. Moreover, for the case reported here (case 2), it is important to emphasize the need for advanced imaging, such as CT, to confirm that the cat had cholesteatoma and not just keratin accumulation secondary to the polyp. Also, the etiology multifactorial with chronic inflammation at least as a predisposing factor, but congenital malformation and displacement of epithelium are also cited. The pathophysiology suggested migration of the squamous epithelium from the external ear canal or from the external surface of the tympanic membrane after rupture, which not only develops from infections, but can also occur as a result of trauma or from conditions such as polyps, which can alter pressure within the middle ear and can rupture the membrane.<sup>10</sup>

The recommended treatment for cholesteatoma in dogs and humans is surgical intervention.<sup>2,7,12</sup> However, in one study,<sup>2</sup> only 9/19 dogs that were treated surgically showed resolution of the clinical signs with a follow-up of 3–95 months. Additionally, surgical intervention has been associated with high recurrences in dogs (41.66%<sup>2</sup> and 53%<sup>11</sup>). It is important to emphasize that postsurgical recurrences are likely due to chronicity, severity and the challenge of completely removing the keratinous material from the bulla.<sup>2,5,8</sup> In the first case report,<sup>7</sup> the cat had undergone a ventral bulla osteotomy 13 years prior to the nasopharyngeal polyp; however, the cat was treated with antibiotics for 3 years, and was euthanized after developing neurologic signs. In the other report,<sup>8</sup> the cat had a good outcome following ventral bulla osteotomy. Both cats in this present report remained stable, with no recurrences for 1 and 6 months post-flushing; however, repeat video-otoscopy and CT with a longer follow-up would have been ideal. Similar to the cats in this report, one study in dogs showed that 9/13 ears were successfully treated via video-otoscopy, but four dogs had recurrence of clinical signs with a mean time of 4.3 months post-flushing.<sup>5</sup> The four ears that had recurrence of clinical signs had a more advanced disease compared with those that did not have a recurrence.<sup>5</sup> In a recent report of middle ear cholesteatoma in a dog,<sup>12</sup> video-otoscopic removal of debris was repeated four times after recurrences. Repeat CT scans showed only mild progression of the disease and only mild clinical signs over 23.4 months. Early diagnosis of cholesteatoma seems to be associated with a lower chance of recurrence.<sup>2,5,12</sup> The cats in this report had cholesteatomas to the external and middle ears, without affecting the surrounding

structures, with mild bulla expansion and sclerosis in one cat. It is unclear whether these bulla changes were due to the cholesteatoma, the polyp or both. These cats remained stable post-flushing; however, although the bulla was thoroughly flushed, it is possible that some of the keratinous material remained present, considering the bulla septum of cats that can impede a thorough flush and the short follow-up period.<sup>2,11,12</sup>

Surgery appears to be the preferable treatment in dogs, despite the reported recurrence rate.<sup>2</sup> Although studies are needed to investigate the ideal treatment of cholesteatoma in cats, conservative video-otoscopic flushing may be a palliative alternative treatment to surgery, similar to the reports in dogs, especially in cats with an early diagnosis and less severe disease and when surgical intervention is not possible. However, considering the aggressive nature of this condition, frequent and longer follow-up times, with otoscopic examinations and repeated CT scans and flushings to remove remaining material, should be performed to assure resolution and reduce the chance of recurrence.

## Conclusions

This report provides further evidence of middle ear cholesteatoma in cats, which can be easily visualized, sampled and potentially palliatively managed, through video-otoscopy and flushing. Additionally, cholesteatoma can also affect young cats and polyps may be a concurrent abnormality. Owing to the limited information about feline aural cholesteatoma, future reports including a larger number of cats will better elucidate the etiopathogenesis, progression and best treatment of aural cholesteatoma in cats.

**Conflict of interest** The authors declared no potential conflicts of interest with respect to the research, authorship, and/or publication of this article.


**Funding** This study was funded by Coordenação de Aperfeiçoamento de Pessoal de Nível Superior – Brasil (CAPES) – finance code 001. Article execution was financed by the project supervisor.

**Ethical approval** The work described in this manuscript involved the use of non-experimental (owned or unowned) animals. Established internationally recognized high standards ('best practice') of veterinary clinical care for the individual patient were always followed and/or this work involved the use of cadavers. Ethical approval from a committee was therefore not specifically required for publication in *JFMS*

*Open Reports*. Although not required, where ethical approval was still obtained it is stated in the manuscript.

**Informed consent** Informed consent (verbal or written) was obtained from the owner or legal custodian of all animal(s) described in this work (experimental or non-experimental animals, including cadavers) for all procedure(s) undertaken (prospective or retrospective studies). For any animals or people individually identifiable within this publication, informed consent (verbal or written) for their use in the publication was obtained from the people involved.

**ORCID ID** Rafaella Tortoriello  <https://orcid.org/0000-0002-8433-5240>

Natália Lôres Lopes  <https://orcid.org/0000-0003-4659-5815>

## References

- Lucas R, Correa S, Calabria CK, et al. **Otitis**. In: Larsson CE and Lucas R (eds). *Tratado de Medicina Externa-Dermatologia Veterinária*. 2nd edn. São Caetano do Sul: São Paulo, 2016, pp 917–954.
- Hardie EM, Linder KE and Pease A. **Aural cholesteatoma in twenty dogs**. *Vet Surg* 2008; 37: 763–770.
- Travetti O, Giudice C, Greci V, et al. **Computed tomography features of middle ear cholesteatoma in dogs**. *Vet Radiol Ultrasound* 2010; 51: 374–379.
- Newman AW, Wstey CM, McDonough S, et al. **Cholesteatoma and meningoencephalitis in a dog with chronic otitis externa**. *Vet Clin Pathol* 2015; 44: 157–163.
- Imai A, Kondo H, Suganuma T, et al. **Clinical analysis and nonsurgical management of 11 dogs with aural cholesteatoma**. *Vet Dermatol* 2019; 30: 42–e12.
- Prasannaraj T, Narajit SD and Narasimhan I. **Aural polyps: safe or unsafe disease?** *Am J Otolaryngol* 2003; 24: 155–158.
- Alexander A, Mahoney P, Scurrall E, et al. **Cholesteatoma in a cat**. *JFMS Open Rep* 2019; 5. DOI: 10.1177/2055116919848086.
- Herberger A, Hammond J, Miller A, et al. **MRI of a middle ear cholesteatoma in a cat**. *Vet Radiol Ultrasound* 2022; 63: E16–E20.
- Greci V, Travetti O, Di Giancamillo M, et al. **Middle ear cholesteatoma in 11 dogs**. *Can Vet J* 2011; 52: 631–636.
- Gilberto N, Custódio S, Colaço T, et al. **Middle ear congenital cholesteatoma: systematic review, meta-analysis and insights on its pathogenesis**. *Eur Arch Otorhinolaryngol* 2020; 277: 987–998.
- Chin-Lung K, Shiao AS, Yung M, et al. **Updates and knowledge gaps in cholesteatoma research**. *Biomed Res Int* 2015; 2015. DOI: 10.1155/2015/854024.
- Vanhamäki LM, Seppänen R, Candido, et al. **Long-term non-surgical management of canine aural tympanokeratoma with repeated removal of middle ear keratinous debris and CT follow-up**. *Scand J Med Sci Sports* 2007; 17: 230–237.